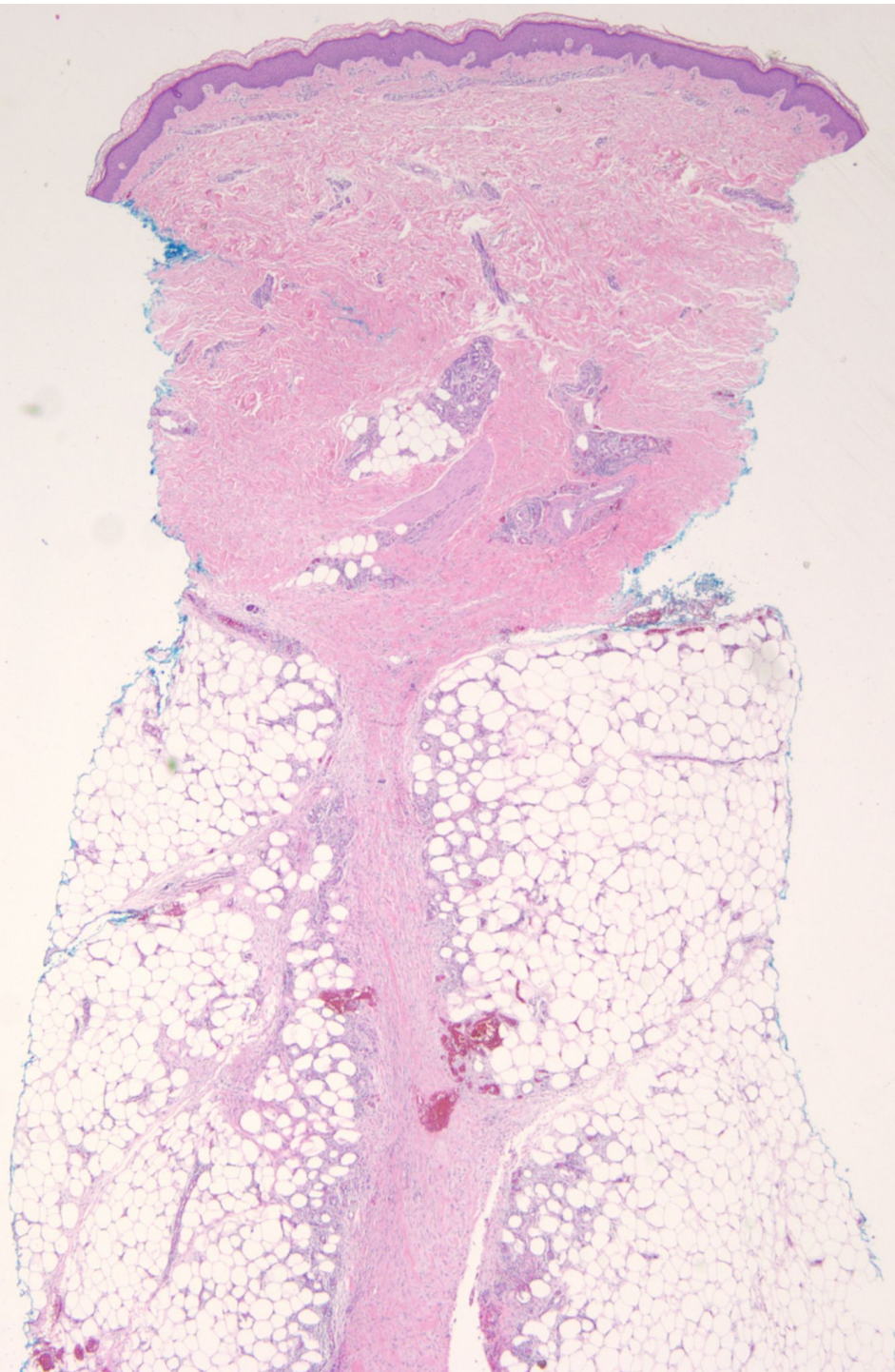
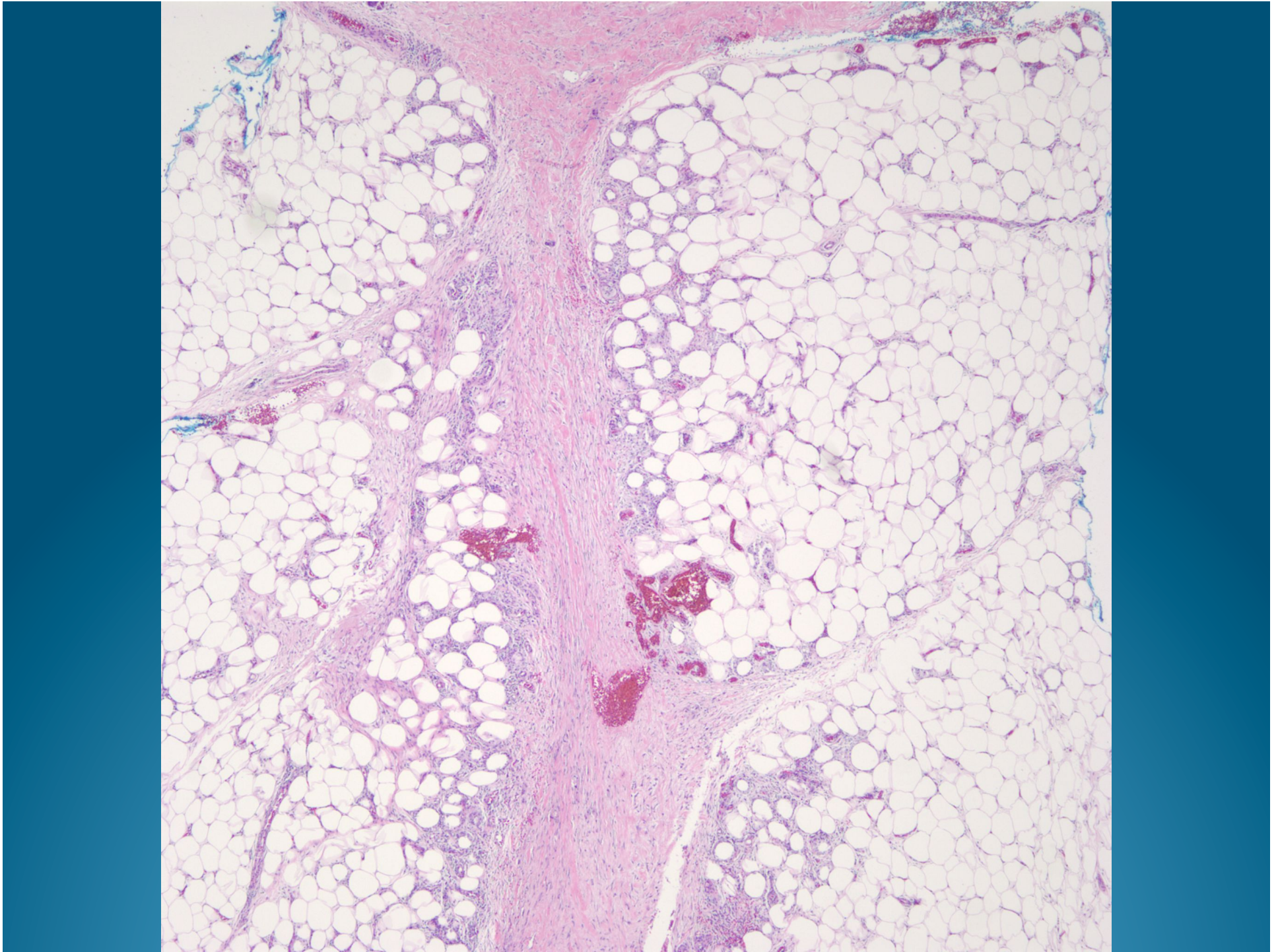
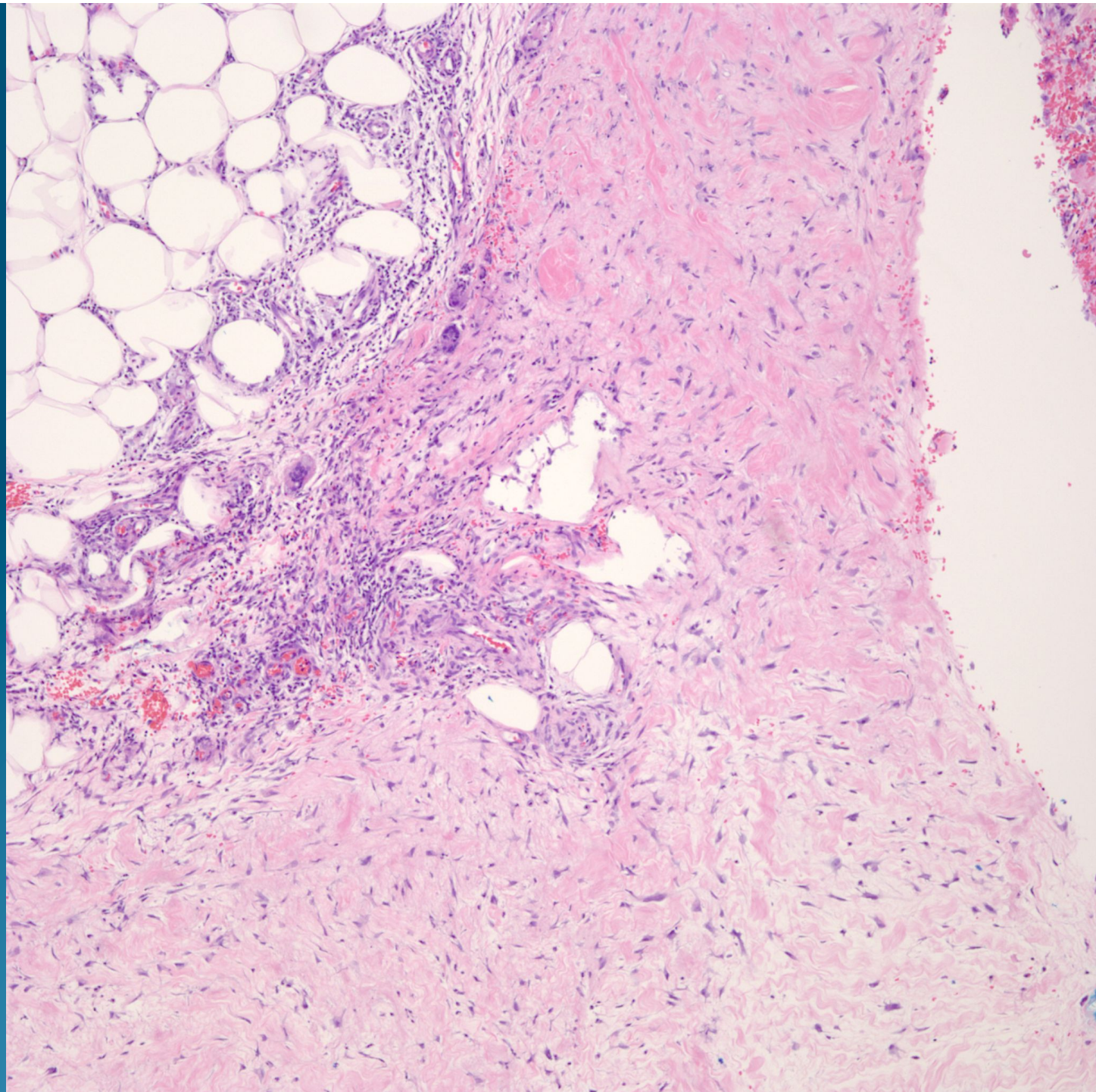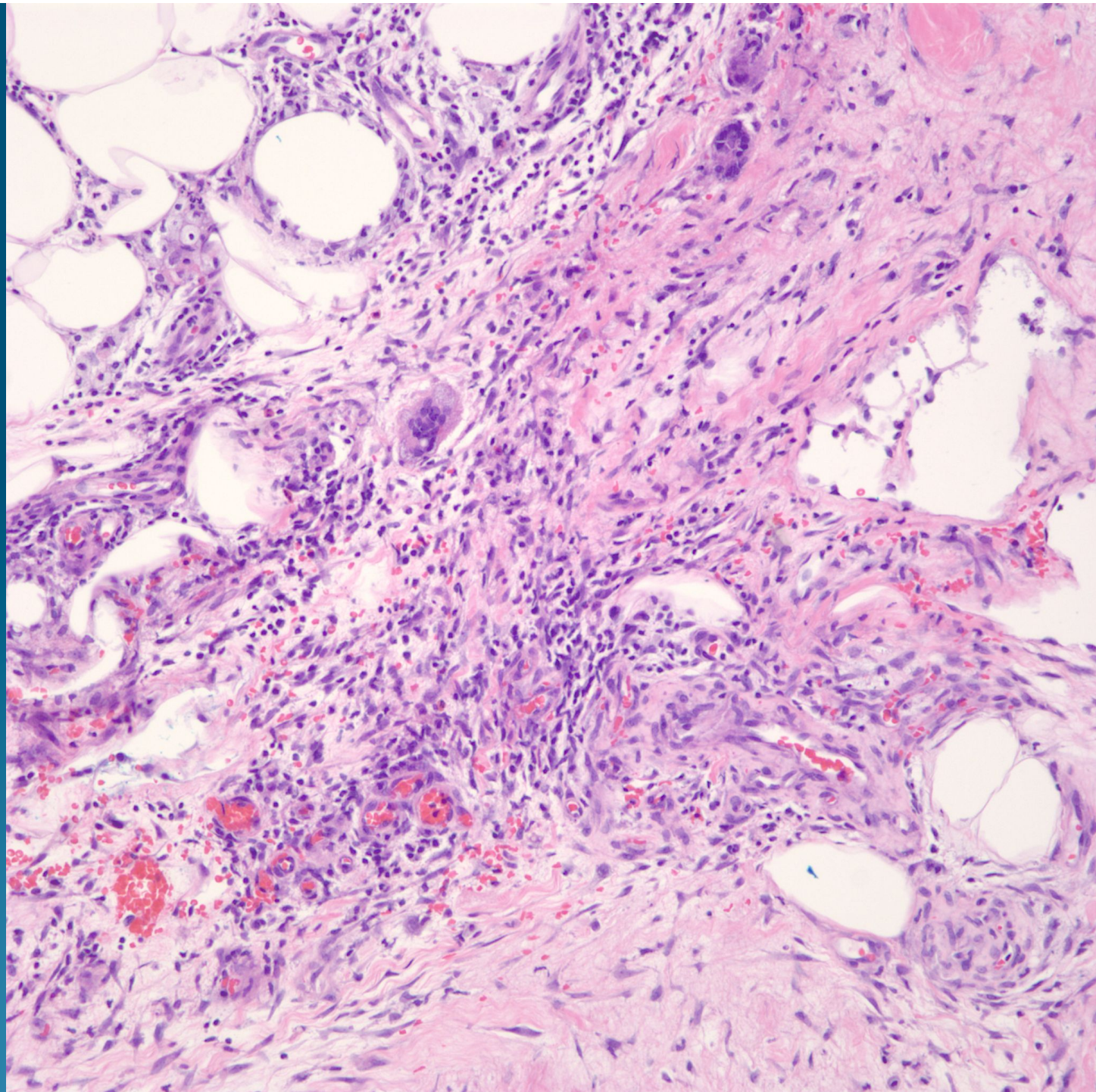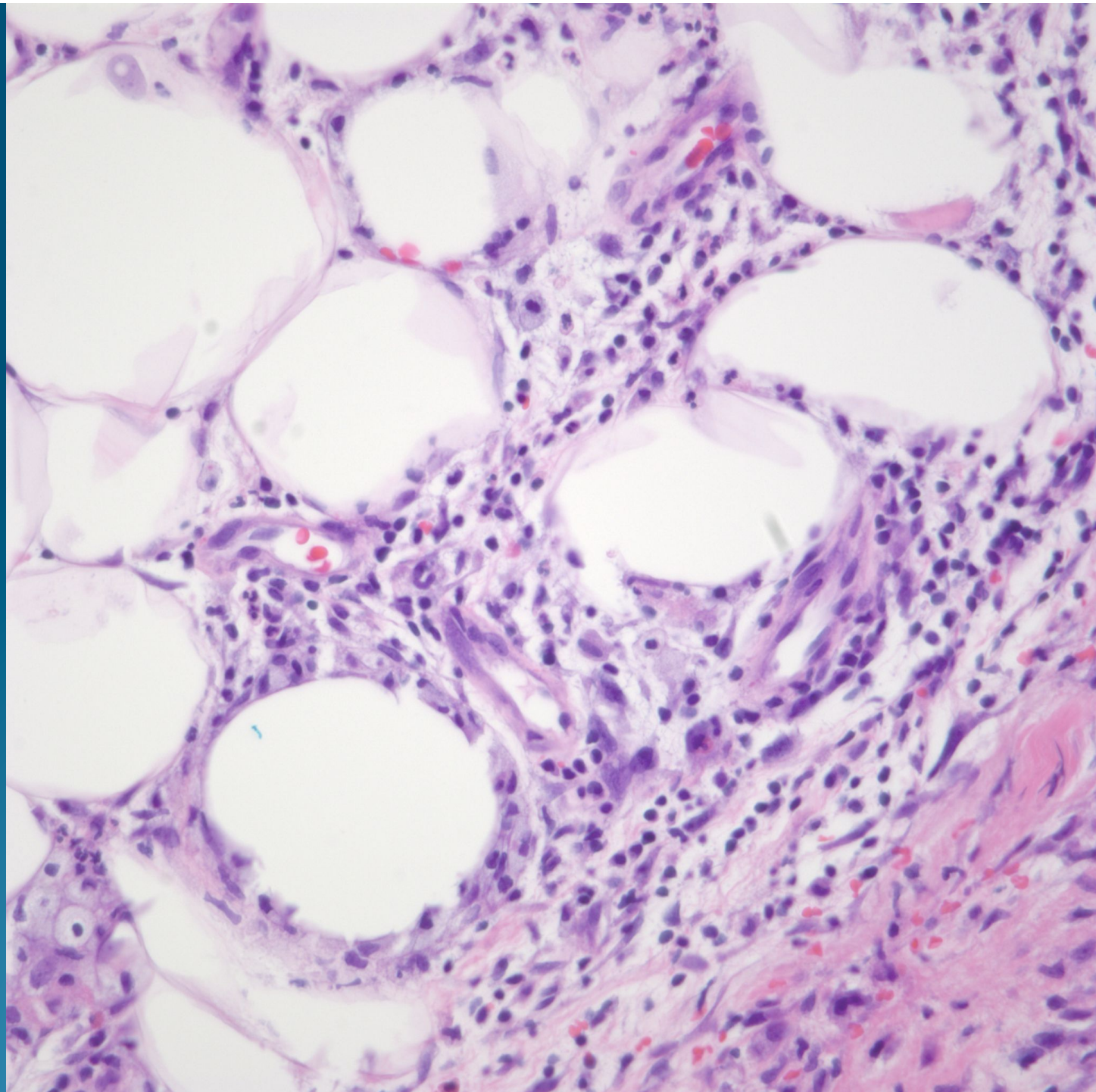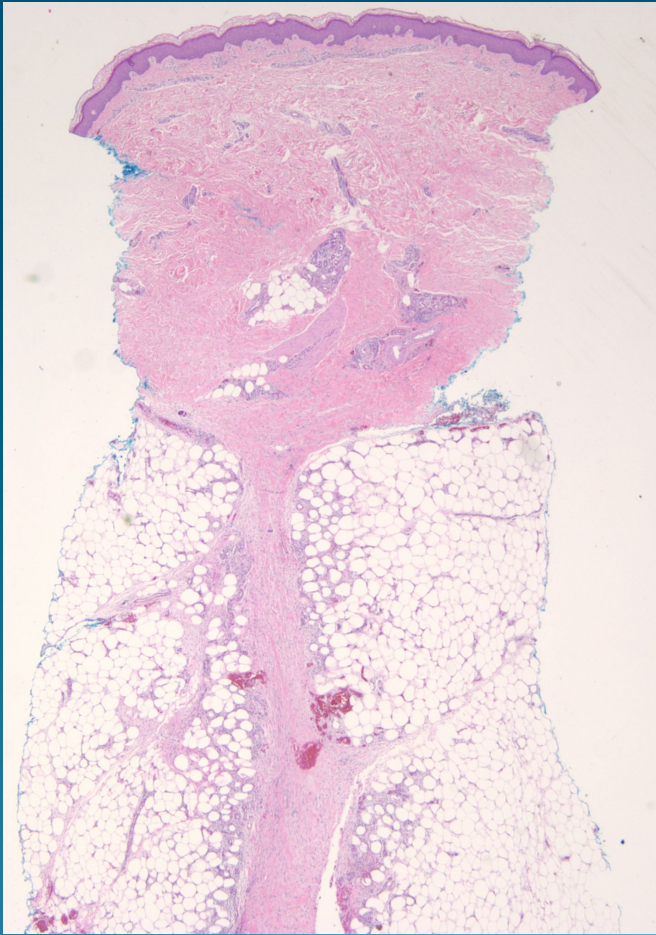
# What is the best diagnosis?

- A. Erythema induratum
- B. Erythema elevatum diutinum
- C. Erythema multiforme
- D. Erythema gyratum repens
- E. Erythema nodosum

# Erythema nodosum



# Pearls



- Predominately septal panniculitis
- No vasculitis
- Scattered giant cells
- Acute cases may mimic infectious process, requiring special stains to rule out infection
- Overlap with some cases of Behcet's syndrome